

## FETAL MRI RISKS: A REVIEW

ADEYEMI O.F<sup>1</sup> and G. G. Nyam<sup>1</sup>

1. Department of Physics, University of Abuja, Abuja, Nigeria

IJASR 2021  
VOLUME 4  
ISSUE 4 JULY – AUGUST

ISSN: 2581-7876

**Abstract:** The use of MRI for production of quality images has improve on diagnosis and studies of health related issue in medicine. This review help to understand and analyse the risk involve infetalmri scanning that can be harmful to the fetus, mother and mri operator

**Keywords:** MRI, Projectile Effect, Vertigo, SAR

### 1. INTRODUCTION

#### 1.1 FETAI MRI

Although ultrasound is a routine part of prenatal care, it is limited in its ability to visualize the developing brain and detect abnormalities in brain development. With recent technological advances, fetal magnetic resonance imaging (MRI) has become a safe and efficient way to evaluate the fetal brain. Fetal MRI allows us to evaluate the fetal brain with greater detail compared to ultrasound. As a result, fetal MRI can detect abnormalities in the fetal brain that are not visible on prenatal ultrasound. Because of this, fetal MRI is being increasingly performed as part of clinical care when a brain abnormality is suspected on prenatal ultrasound and/or when the foetus is at increased risk of developing a brain abnormality.(Saleem, 2014)

Fetal MRI is a non-invasive imaging test that offers detailed information about anatomic structures of the fetus, providing clear, high-resolution images. Fetal MRI can supplement the information obtained from your high-resolution fetal ultrasound and can provide additional information regarding your baby's diagnosis. It is performed in the 2nd or 3rd trimester of pregnancy. MRI may be used to confirm an ultrasound diagnosis or add significant diagnostic information in complex cases. (Children's Hospital of Philadelphia, n.d.)

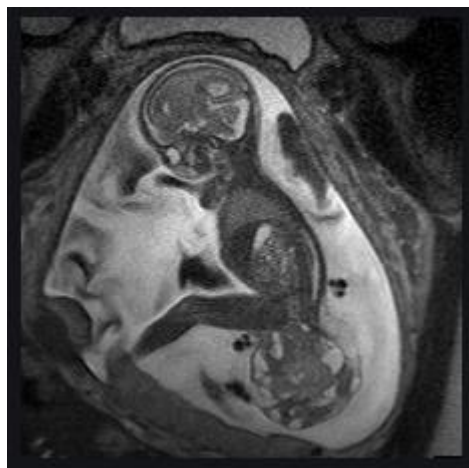


Fig. 1 An example of a fetasmri scan

#### 1. POSSIBLE HAZZARD

As all health care equipment MRI has its own possible hazard attach to it for the MR operator the mother and child, but these effect can be reduce if great care and due diligent are taking before and during scanning. In this review we

are going to go through some of these hazards and see what majors can be taking to reduces them and improve on the use of MRI for fetal scanning especially in the developing countries.

### 2.1 Translational Force and Torque and Projectile Injury

One of the main hazard associated with MRI is the **Missile effect** (or projectile effect) where ferromagnetic material that are accidentally brought in to the scanning room are attracted by the static magnetic field of the MRI scanner (i.e. oxygen bottles, scissors, chairs, etc.). This effect involves the risk of impact with the patient (mother and child) or the radiographer. Thus it is a major risk factor for both patient and personnel safety, and could also result in severe material damage. Specifically, the "force" with which the ferromagnetic object is attracted to the centre of the magnet is directly proportional to the intensity of the static magnetic field ( $B_0$ ), to the mass of the object and, inversely proportional to the distance cube.(Panych & Madore, 2018)(Tsai et al., 2015).

Medical devices and implants contain varying amounts of ferromagnetic material and can be subject to these forces from the static magnetic fields though most medical devices are MR safe but some require extra care when scanning.

### 2.2 Vertigo

When scanning in fields greater than 2T there is this sensation that you, or the environment around you, is moving or spinning. This feeling may be barely noticeable, or it may be so severe that you find it difficult to keep your balance and do everyday tasks.(Glover et al., 2007). This effect increases with increase in field strength and may unlikely be noticeable at normal clinical scanning but for higher fields the effect of vertigo might be more in the fetus than the mother as the position in which the fetus lying with respect to the field cannot be expertly predicted and may lying perpendicular to the magnetic field which could have effect on the flow of blood as describe by (Kinouchi et al., 1996).

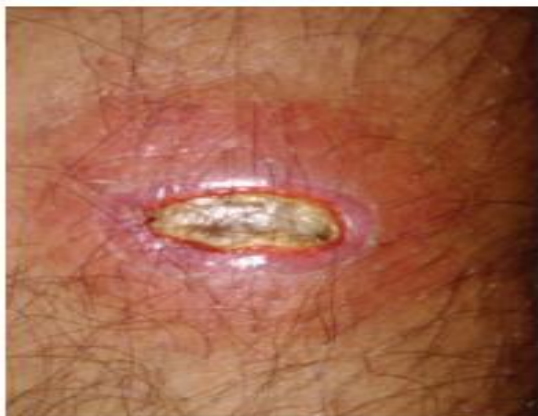### 2.3 SAR

The amount of energy deposited by the radiofrequency coil is quantified in SAR measured in watt per kilogram (W/kg). One of the major concern or risk associated with RF is the heating as heating or rapid rise in temperature could affect the fetus(Lancaster, 2011)(Isbrucker et al., 2006).

At present it is very difficult to know the temperature of a fetus for any given SAR since the fetus is embedde in the mothers abdomen which is at a temperature of 37°C hence it would be advisable to scanned at normal SAR

### 2.4 Thermal injury

Thermal injury from MR imaging is uncommon, with 419 reported cases between 2000 and 2010 in the United States (23). However, burns can be severe, life threatening, and difficult to predict.(Tsai et al., 2015)



a.



b.

**Figure 2. Direct contact burn. (a) Photograph shows a thirddegree burn on a patient’s calf, which was pressed against the cable of the radiofrequency coil. (b) Photograph shows a phasedarray coil similar to the one involved in the incident. The coil cable showed no indication of a burn. Arrow = approximate contact point.(Tsai et al., 2015)**

Most RF burns in MR especially in adult are as a result of contact with extraneous electrical conductors (including metal implants, ECG leads, and RF coils leads), close contact with the RF coils, and conduction loops setup through the skin (e.g., by allowing skin of the shins or thighs to touch). None of these sources of localized burning are likely to be a problem for the fetuses since fetal and maternal system are independent

### 2.5 Acoustic Injury

There are concern across various level that the noise level generated by the gradient coil of MRI may have some effect on the fetus ear and the mother hence adult are advise to wear ear protection to reduce the effect of the noise. The noise level reaching the fetus should be greatly reduce as the main means by which sound will travel to the fetus is through the wall of the mother body and amniotic fluid this reduce the noise level(Letowski et al., 1992). Hence loud pulse sequence should be avoided if possible and mother should be mechanically isolated from the bed as much as possible.

### 2.6 Imaging personnel

Pregnant radiologists, technicians, and other health care providers are allowed to work around and in the MR imaging environment throughout all stages of their pregnancy. Although they are allowed to position patients, image and archive, inject contrast material, place radiofrequency coils, and enter the MR imaging room in response to an emergency, it is recommended that they do not remain in the MR imaging bore or magnet room during data acquisition or imaging(Kanal et al., 2013)

## 2. CONCLUSION

Many research, studies and review have been conducted on the safety of fetalMRI but from the review we can see that there are no great risks to the development of the fetus though one must be extremely care when conducting scans and make sure all possible precaution are taking to avoid accident in the scanning room.

## 3. REFERENCES

1. Children’s Hospital of Philadelphia, n.d. FetalMRI: <https://www.chop.edu/treatments/ultrafast-fetal-magnetic-resonance-imaging-mri>
2. Glover, P. M., Cavin, I., Qian, W., Bowtell, R., & Gowland, P. A. (2007). Magnetic-field-induced vertigo: A theoretical and experimental investigation. *Bioelectromagnetics*, 28(5), 349–361. <https://doi.org/10.1002/bem.20316>
3. Isbrucker, R. A., Edwards, J. A., Wolz, E., Davidovich, A., & Bausch, J. (2006). Safety studies on epigallocatechin gallate (EGCG) preparations. Part 3: Teratogenicity and reproductive toxicity studies in rats. *Food and Chemical Toxicology*, 44(5), 651–661. <https://doi.org/10.1016/j.fct.2005.11.002>
4. Kanal, E., Barkovich, A. J., Bell, C., Borgstede, J. P., Bradley, W. G., Froelich, J. W., Gimbel, J. R., Gosbee, J. W., Kuhni-Kaminski, E., Larson, P. A., Lester, J. W., Nyenhuis, J., Schaefer, D. J., Sebek, E. A., Weinreb, J., Wilkoff, B. L., Woods, T. O., Lucey, L., & Hernandez, D. (2013). ACR guidance document on MR safe practices: 2013. *Journal of Magnetic Resonance Imaging*, 37(3), 501–530. <https://doi.org/10.1002/jmri.24011>
5. Kinouchi, Y., Yamaguchi, H., & Tenforde, T. S. (1996). Theoretical analysis of magnetic field interactions with aortic blood flow. *Bioelectromagnetics*, 17(1), 21–32. [https://doi.org/10.1002/\(sici\)1521-186x\(1996\)17:1<21::aid-bem3>3.0.co;2-8](https://doi.org/10.1002/(sici)1521-186x(1996)17:1<21::aid-bem3>3.0.co;2-8)
6. Lancaster, P. A. L. (2011). Causes of birth defects: Lessons from history. *Congenital Anomalies*, 51(1), 2–5. <https://doi.org/10.1111/j.1741-4520.2010.00311.x>
7. Letowski, T. R., Richards, W. D., & Burchfield, S. B. (1992). Transmission of sound, vibration through earmold materials. *Hear Instrum*, 43(12), 11–15.
8. Panych, L. P., & Madore, B. (2018). The physics of MRI safety. *Journal of Magnetic Resonance Imaging*, 47(1), 28–43. <https://doi.org/10.1002/jmri.25761>

9. Saleem, S. N. (2014). Fetal MRI: An approach to practice: A review. *Journal of Advanced Research*, 5(5), 507–523. <https://doi.org/10.1016/j.jare.2013.06.001>
10. Tsai, L. L., Grant, A. K., Mortelet, K. J., Kung, J. W., & Smith, M. P. (2015). A practical guide to MR imaging safety: What radiologists need to know. *Radiographics*, 35(6), 1722–1737. <https://doi.org/10.1148/rg.2015150108>